

BRAIN PERFUSION STUDY (Tc-99m-ECD, Tc-99m-HMPAO)

Overview

- The Brain Perfusion Study produces SPECT tomograms depicting the distribution of blood flow and perfusion to the various structures of the brain (1).

Indications

- Diagnosis of Alzheimer's disease (2,3).
- Localization of seizure foci (4-6).
- Evaluation of carotid blood flow prior to surgical occlusion (7).
- Diagnosis of brain death (8,9).
- Evaluation of brain injury (10).

Examination Time

- 1 hour.

Patient Preparation

- The imaging room should be quiet and dimly lit (11,12).
- Instruct the patient not to read or speak.
- Place an intravenous line in advance so the patient does not experience pain from the needle puncture at the time of radiopharmaceutical injection.

Equipment & Energy Windows

- Camera: Rotating gamma camera. Two or three-headed gamma camera imaging system is preferred (13).
- Collimator (14): Low energy, high resolution, parallel hole collimator.
- Energy window: 20% window centered at 140 keV.
- Computer with SPECT software.

Radiopharmaceutical, Dose, & Technique of Administration

- Radiopharmaceutical (15,16): Tc-99m-ethyl cysteinate dimer (Tc-99m-ECD).
θ Tc-99m-hexamethylpropyleneamineoxime (Tc-99m-HMPAO).
- Dose: 20 mCi (740 MBq).
- Technique of administration: Through an existing intravenous line.

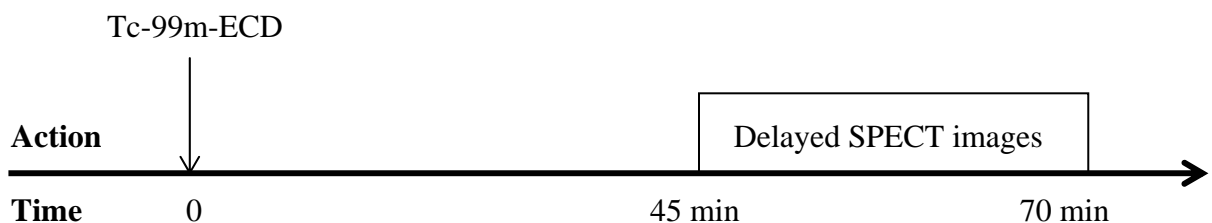
Patient Position & Imaging Field

- Patient position:
 1. Supine with the head in a head holder secured with a velcro strap.
 2. Flex the head so that the cerebellum is included in the field of view.
- Imaging field: Entire brain including the cerebellum.

Acquisition Protocol

- Time from injection to beginning image acquisition (13):
 - > Tc-99m-ECD : 45 minutes.
 - > Tc-99m-HMPAO: 90 minutes.
- Have the patient void prior to image acquisition to maximize patient comfort (13).
- Image acquisition parameters:
 1. Degrees of rotation: 360°.
 2. Number of images: 64.
 3. Time per image: Approximately 20 seconds.
 4. Matrix: 128 x 128 pixels.

Protocol Summary Diagram



Data Processing

- Correct the planar images for camera non-uniformity with a high count, e.g. 30 million count, Co-57 flood field image.
- Reconstruct transverse, sagittal, and coronal images (17).
- Correct for attenuation using transmission maps if available (18).
- Construct a 3 dimensional surface display of the brain for dynamic viewing (19).

Optional Maneuvers

- Fast acquisition: Fast acquisition methods may be used in patients who are unable to hold still for prolonged periods of time (20).
- Seizures may be produced pharmacologically with pentylenetetrazol for ictal imaging (21).
- Acetazolamide may be used to increase the sensitivity of brain perfusion imaging for cerebrovascular ischemia (22,23):
 1. Contraindications (23):
 - a) allergy to sulfonamides (Acetazolamide is a non-bacteriostatic sulfonamide.).
 - b) active transient ischemic attacks (This is not an absolute contraindication.).
 2. Side effects - occur in about 50% of patients & last for about 15 minutes (23):
 - a) numbness around mouth or fingers.
 - b) lightheadedness or blurred vision.
 - c) flushed feeling around face and neck.
 3. Inject 1 gm of acetazolamide intravenously over 1-2 minutes.
 4. Wait 25 minutes and then inject the radiopharmaceutical.
 5. Wait 20 minutes and acquire images in the usual manner.
 6. A baseline brain perfusion study without acetazolamide is performed one or more days later.
 7. Adenosine or dipyridamole may be used instead of acetazolamide (24,25).
- Diagnosis of brain death (8,9):
 1. Position the gamma camera for an ANT dynamic study of the head.
 2. Inject radiopharmaceutical in a bolus fashion and acquire 2 second serial analog and/or digital images for at least 30 seconds.
 3. Approximately 15 minutes after injection, acquire planar images in the ANT and right or left LAT projections.
 4. SPECT imaging may be performed if necessary and feasible.

- Quantification: Activity in the tomograms may be quantitated on a regional basis (26,27).
- Interictal images may be subtracted from ictal images in the same patient (28).
- Superimposition of perfusion and anatomic images: Images may be superimposed on corresponding magnetic resonance images with computer assistance (29,30).

Principle Radiation Emission Data - Tc-99m (31)

- Physical half-life = 6.01 hours.

Radiation	Mean % per disintegration	Mean energy (keV)
Gamma-2	89.07	140.5

Dosimetry - Tc-99m-ECD (32)

Organ	rads/20 mCi	mGy/740 MBq
Bladder wall		
2 hour void	2.2	22.0
4.8 hour void	5.4	54.0
Gallbladder wall	1.8	18.0
Large intestine	1.2	12.0
Small intestine	0.7	7.0
Kidneys	0.5	5.4
Brain	0.4	4.0

Dosimetry - Tc-99m-HM-PAO (33)

Organ	rads/20 mCi	mGy/740 MBq
Lachrymal glands	5.2	52.0
Gallbladder wall	3.8	38.0
Kidneys	2.6	26.0
Thyroid	2.0	20.0
Large intestine	1.6	16.0
Liver	1.1	11.0
Small Intestine	0.9	9.0
Bladder wall	0.9	9.0
Brain	0.5	5.0
Ovaries	0.5	5.0
Total body	0.3	3.0
Testes	0.1	1.0

References

1. Payne JK, Trivedi MH, Devous MD: Comparison of technetium-99m-HMPAO and xenon-133 measurements of regional cerebral blood flow by SPECT. J Nucl Med 37:1735-1740, 1996.
2. Herholz K, Schopphoff H, Schmidt M, et al: Direct comparison of spatially normalized PET and SPECT scans in Alzheimer's disease. J Nucl Med 43:21-26, 2002.
3. Bonte FJ, Weiner MF, Bigio EH, et al: Brain blood flow in the dementias: SPECT with histopathologic correlation in 54 patients. Radiology 202:793-797, 1997.
4. Devous MD, Thisted RA, Morgan GF, et al: SPECT brain imaging in epilepsy: A meta-analysis. J Nucl Med 39:285-293, 1998.
5. Spanake MV, Spencer SS, Corsi M, et al: Sensitivity and specificity of quantitative difference SPECT analysis in seizure localization. J Nucl Med 40:730-736, 1999.
6. Kaiboriboon K, Bertrand ME, Osman MM, et al: Quantitative analysis of cerebral blood flow patterns in mesial temporal lobe epilepsy using composite SISCOM. J Nucl Med 46:38-43, 2005.
7. Sugawara Y, Kikuchi T, Ueda T, et al: Usefulness of brain SPECT to evaluate brain tolerance and hemodynamic changes during temporary balloon occlusion test and after permanent carotid occlusion. J Nucl Med 43:1616-1623, 2002.
8. Spieth ME, Ansari AN, Kawada TK, et al: Direct comparison of Tc-99m DTPA and Tc-99m HMPAO for evaluating brain death. Clin Nucl Med 19:867-872, 1994.
9. Kurtek RW, Lai KK, Tauxe WN, et al: Tc-99m hexamethylpropylene amine oxime scintigraphy in the diagnosis of brain death and its implications for the harvesting of organs used for transplantation. Clin Nucl Med 25:7-10, 2000.
10. Jacobs A, Put E, Ingels M, et al: One-year follow-up of technetium-99m-HMPAO SPECT in mild head injury. J Nucl Med 37:1605-1609, 1996.
11. Woods SW, Hegeman IM, Zubal G, et al: Visual stimulation increases technetium-99m-HMPAO distribution in human visual cortex. J Nucl Med 32:210-215, 1991.
12. Scao YL, Jezequel J, Robier A, et al: Reliability of low-frequency auditory stimulation studies associated with technetium-99m hexamethylpropylene amine oxime single-photon emission tomography. Eur J Nucl Med 20:387-390, 1993.
13. Juni JE, Waxman AD, Devous MD, et al: Procedure guideline for brain perfusion SPECT using technetium-99m radiopharmaceuticals. J Nucl Med 39:923-926, 1998.
14. Li J, Jaszczak RJ, Turkington TG, et al: An evaluation of lesion detectability with cone-beam, fanbeam and parallel-beam collimation in SPECT by continuous ROC study. J Nucl Med 35:135-140, 1994.
15. Asenbaum S, Brucke T, Pirker W, et al: Imaging of cerebral blood flow with technetium-99m-HMPAO and technetium-99m-ECD: A comparison. J Nucl Med 39:613-618, 1998.
16. van Dyck CH, Lin CH, Smith EO, et al: Comparison of technetium-99m-HMPAO and technetium-99m-ECD cerebral SPECT images in Alzheimer's disease. J Nucl Med 37:1749-1755, 1996.

17. Kauppinen T, Koskinen MO, Alenius S, et al: Improvement of brain perfusion SPET using iterative reconstruction with scatter and nonuniform attenuation correction. Eur J Nucl Med 27:1380-1386, 2000.
18. Licho R, Glick SJ, Xia W, et al: Attenuation compensation in Tc-99m-SPECT brain imaging: A comparison of the use of attenuation maps derived from transmission versus emission data in normal scans. J Nucl Med 40:456-463, 1999.
19. Hashikawa K, Matsumoto M, Moriwake H, et al: Three-dimensional display of surface cortical perfusion by SPECT: Application in assessing Alzheimer's disease. J Nucl Med 36:690-696, 1995.
20. Oshima M, Tadokoro M, Sakuma S: Comparison of Tc-99m HMPAO fast SPECT with Tc-99m HMPAO conventional SPECT in patients with acute stroke. Clin Nucl Med 17:18-22, 1992.
21. Calcagni ML, Giordano A, Bruno I, et al: Ictal brain SPET during seizures pharmacologically provoked with pentylentetrazol: A new diagnostic procedure in drug-resistant epileptic patients. Eur J Nucl Med 29:1298-1306, 2002.
22. Okazawa H, Yamauchi H, Sugimoto K, et al: Differences in vaso dilatory capacity and changes in cerebral blood flow induced by acetazolamide in patients with cerebrovascular disease. J Nucl Med 44:1371-1378, 2003.
23. Burt RW, Witt RM, Cikrit D, et al: Carotid artery disease: Evaluation with acetazolamide-enhanced Tc-99m HMPAO SPECT. Radiology 182:461-466, 1992.
24. Soricelli A, Cuocolo A, Romano M, et al: Comparison between adenosine and acetazolamide for neuroactivation with single photon emission tomography. Eur J Nucl Med 34:830, 1993.
25. Hwang TL, Sainz A, Farrell JJ, et al: Brain SPECT with dipyridamole stress to evaluate cerebral blood flow reserve in carotid artery disease. J Nucl Med 37:1595-1599, 1996.
26. Bartenstein P, Minoshima S, Hirsch C, et al: Quantitative assessment of cerebral blood flow in patients with Alzheimer's disease by SPECT. J Nucl Med 38:1095-1101, 1997.
27. Claus JJ, van Harskamp F, Breteler MMB, et al: Assessment of cerebral perfusion with single-photon emission tomography in normal subjects and in patients with Alzheimer's disease: Effects of region of interest selection. Eur J Nucl Med 21:1044-1051, 1994.
28. Lewis PJ, Siegel A, Siegel AM, et al: Does performing image registration and subtraction in ictal brain SPECT help localize neocortical seizures? J Nucl Med 41:1619-1626, 2000.
29. Stokking R, van Isselt JW, van Rijk PP, et al: Integrated visualization of functional and anatomic brain data: A validation study. J Nucl Med 40:311-316, 1999.
30. Pfluger T, Vollmar C, Wismuller A, et al: Quantitative comparison of automatic and interactive methods for MRI-SPECT image registration of the brain based on 3-dimensional calculation of error. J Nucl Med 41:1823-1829, 2000.
31. 43-Tc-99m: In MIRD: Radionuclide Data and Decay Schemes, DA Weber, KF Eckerman, AT Dillman, JC Ryman, eds, Society of Nuclear Medicine, New York, 1989, pp 178-179.

32. Holman BL, Hellman RS, Goldsmith SJ, et al: Biodistribution, dosimetry, and clinical evaluation of technetium-99m ethyl cysteinate dimer in normal subjects and in patients with chronic cerebral infarction. J Nucl Med 30:1018-1024, 1989.
33. Soundy RG, Tyrrell DA, Pickett RD, et al: The radiation dosimetry of Tc-99m-exametazime. Nucl Med Commun 11:791-799, 1990.

Normal Findings

- > Lobaugh NJ, Caldwell CB, Black SE, et al: Three brain SPECT region-of-interest templates in elderly people: Normative values, hemispheric asymmetries, and a comparison of single- and multihead cameras. J Nucl Med 41:45-56, 2000.
- > Deutsch G, Mountz JM, Katholi CR, et al: Regional stability of cerebral blood flow measured by repeated technetium-99m-HMPAO SPECT: Implications for the study of state-dependent change. J Nucl Med 38:6-13, 1997.
- > Patterson JC, Early TS, Martin A, et al: SPECT image analysis using statistical parametric mapping: Comparison of technetium-99m-HMPAO and technetium-99m-ECD. J Nucl Med 38:1721-1725, 1997.
- > Koyama M, Kawashima R, Ito H, et al: SPECT imaging of normal subjects with technetium-99m-HMPAO and technetium-99m-ECD. J Nucl Med 38:587-592, 1997.
- > Van Laire KJ, Dierckx RA: Brain perfusion SPECT: Age- and sex-related effects correlated with voxel-based morphometric findings in healthy adults. Radiology 221:810-817, 2001.
- > Schiepers C, Verbruggen a, Casaer P, et al: Normal brain perfusion pattern of technetium-99m-ethylcysteinate dimer in children. J Nucl Med 38:1115-1120, 1997.
- > Kuji I, Sumiya H, Niida Y, et al: Age-related changes in the cerebral distribution of Tc-99m-ECD from infancy to adulthood. J Nucl Med 40:1818-1823, 1999.
- > Avery RA, Spencer SS, Spanaki MV, et al: Effect of injection time on postictal SPET perfusion changes in medically refractory epilepsy. Eur J Nucl Med 26:830-836, 1999.
- > Koulibaly PM, Nobili F, Migneco O, et al: Tc-99m-HMPAO and Tc-99m-ECD perform differently in typically hypoperfused areas in Alzheimer's disease. Eur J Nucl Med 30:1009-1013, 2003.